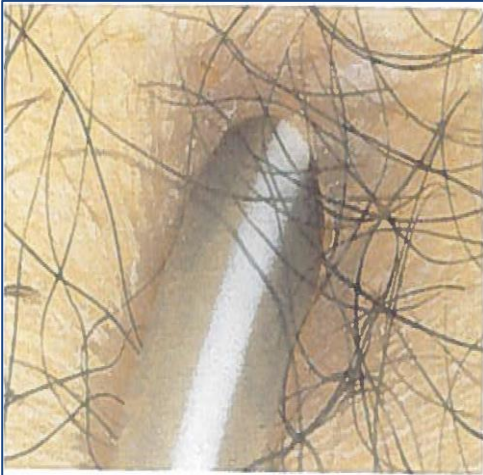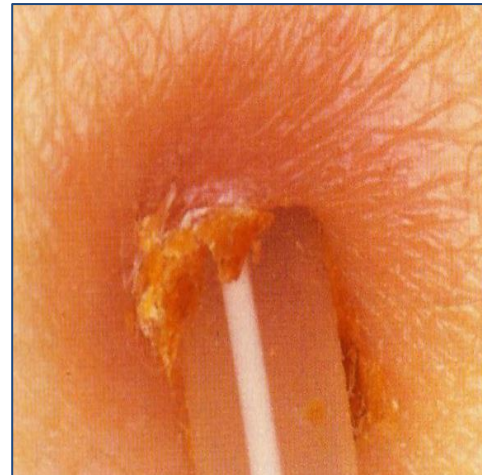

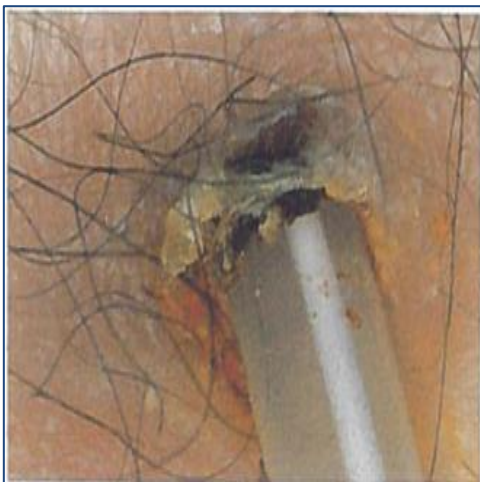
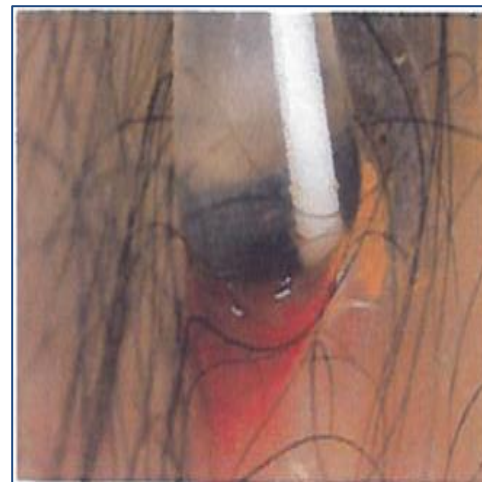Good exit.



Erythema (red, < 13 mm) at the exit site. This exit could be infected, depending on drainage and presence of exuberant granulation tissue in the sinus.



Chronic infection. Large crust with scab and partially dried drainage.



Infected exit. Slightly exuberant granulation tissue in the sinus.

REFERENCE:

Baxter Corporation© (2015) Peritoneal Dialysis Catheter Exit Site Classification Guide, p. 4-10

Adapted in part from: Twardowski, ZJ, and Prowant, BF, Classification of Normal and Diseased Exit Sites, Peritoneal Dialysis International, Vol 16, Supplement 3, 1996.

All photos credit: Dr. Twardowski

© Copyright 2015, Baxter Corporation. All rights reserved. CAMP/MG2/14-0002